

## Vulvar reconstruction using the “lotus petal” fascio-cutaneous flap

Peter A. Argenta<sup>a,\*</sup>, Rhona Lindsay<sup>b</sup>, R. Benjamin Aldridge<sup>c</sup>, Nadeem Siddiqui<sup>b</sup>,  
Kevin Burton<sup>b</sup>, John R.C. Telfer<sup>c</sup>

<sup>a</sup> Division of Gynecologic Oncology, University of Minnesota, Minneapolis, USA

<sup>b</sup> Division of Gynecologic Oncology, Glasgow Royal Infirmary, Glasgow, Scotland, UK

<sup>c</sup> Canniesburn Plastic Surgery Unit, Glasgow Royal Infirmary, Glasgow, Scotland, UK

### HIGHLIGHTS

- We demonstrate that the lotus petal flap is feasible for the closure of moderate- to large-sized vulvar defects.
- Complication rates are reasonable and most morbidity is easily managed.

### ARTICLE INFO

#### Article history:

Received 1 July 2013

Accepted 24 August 2013

Available online 1 September 2013

#### Keywords:

Flap  
Vulva  
Vulvar reconstruction  
Vulvar surgery  
Lotus petal

### ABSTRACT

**Introduction.** Vulvar reconstruction using the “lotus petal” fascio-cutaneous flap offers a relatively novel means to restore symmetry and functionality after extirpative gynecologic or oncologic procedures. We sought to assess the success rates and morbidity in a large series of consecutively treated patients.

**Methods.** We performed a retrospective review of 59 consecutive cases of lotus petal flaps performed at a single institution to more accurately assess success and complication rates.

**Results.** We identified 80 flaps performed among the 59 patients between September 1, 2008 and March 30, 2013. The median (range) age was 59 years (24–89) and the median (range) BMI was 27 kg/m<sup>2</sup> (19–34). The indications for vulvar/perineal excision were as follows: 39 (66.1%) vulvar carcinoma or melanoma, 12 (20.3%) vulvar dysplasia, 5 (8.5%) colorectal disease and 3 (5.1%) cases of hidradenitis suppurativa. The mean defect area, determined by post-fixation pathology specimen was 29 cm<sup>2</sup>. Medical or surgical complications occurred in 36% of patients of which superficial wound separation was the most common (15%). There were no cases of complete flap loss, but partial loss occurred in 7 (8.8%) cases. 3 (5.1%) patients required re-operation prior to discharge with one case requiring skin grafting. Delayed surgical revision was required in 4 patients for partial flap loss (2) or stricture/stenosis (2).

**Conclusion.** The lotus petal flap is safe for use in gynecologic reconstruction, with acceptable short- and long-term complication rates. Previous reports of smaller series likely underestimate the risk of complications through case selection.

© 2013 Elsevier Inc. All rights reserved.

### Introduction

Despite a movement away from radical en bloc resections, larger vulvectomies with or without lymph node dissections remain morbid [1]. Closure of the defect site after larger vulvar excisions presents not only a technical challenge to the surgeon but carries significant medical, functional, and psychosocial implications for the patient. Reconstruction must be tailored to the needs of the patient with consideration of the wound geometry as well as potential secondary complications. For smaller defects, local advancement or rotation flaps generally provide

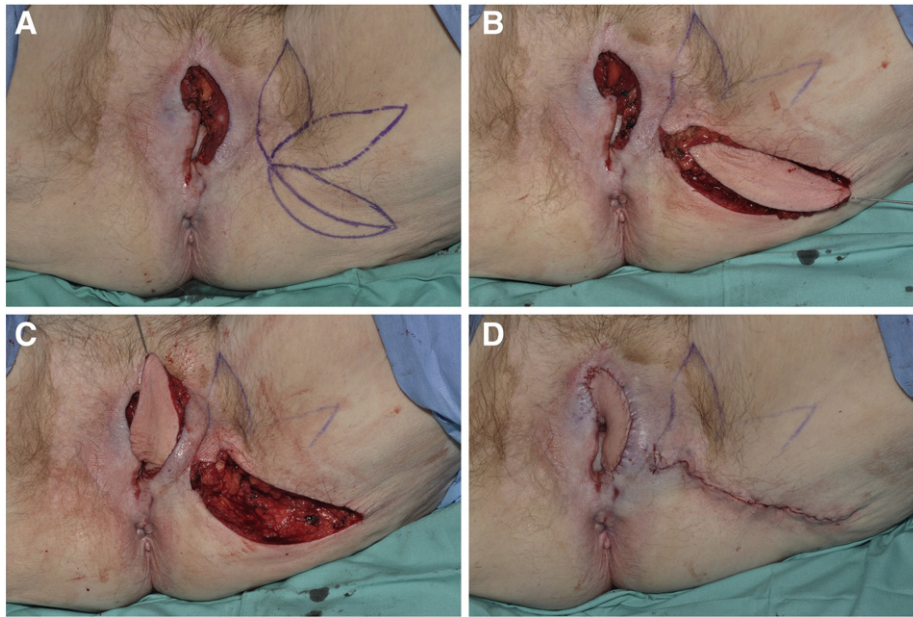
adequate tissue mobility with minimal risk, while often maintaining sensation.

For larger defects, such as seen following exenterative procedures, myocutaneous flaps including vertical or transverse rectus abdominis or gracilis flaps are appropriate as they provide bulk to minimize dead space in the infra-levator defect, as well as skin coverage at the surface. These flaps are typically too bulky for use following local excisions and additionally require tissue donation remote from the defect, creating additional potential for morbidity and disfigurement.

Fascio-cutaneous flaps based on perforators of the pudendal artery provide an excellent potential source of tissue for closure of intermediate to large vulvar defects. The term “lotus petal flap” was first used by Yui and Niranjana, to describe the diversity of axes upon which these flaps can be raised which when superimposed have the appearance of the lotus flower (Fig. 1A) [2]. The posterior-lateral gluteal-fold variation of

\* Corresponding author at: MMC 395, 420 Delaware St SE, Minneapolis, MN 55455, USA. Fax: +1 612 626 0665.

E-mail address: [argenta@umn.edu](mailto:argenta@umn.edu) (P.A. Argenta).



**Fig. 1.** Moderate sized defect extends from perineal body posteriorly across the midline anteriorly, following excision anterior-central squamous carcinoma. Options for tunneled lotus petal flap are displayed forming a “half of a lotus flower” (A). Gluteal fold (lateral-most petal) flap is selected and incised (B). A subcutaneous incision at the lateral aspect of the defect allows the flap to be mobilized medially and fixed in the recipient site with dissolvable suture (C). Flap sewn into place and donor site closed along gluteal fold (D).

the lotus-petal flap has been advocated because in addition to providing a cosmetic donor site, the base geometry does not require sacrifice of the pudendal nerve and thus maintains some sensation in most cases. Multiple authors have reported favorable results with regard to patient tolerance, flap viability and donor site morbidity, though most series have reported fewer than 10 patients, with variably reported selection criteria and duration or intensity of follow-up (Table 1) [3–6]. Larger series, though still small, describe higher rates of flap loss (6–8%) and complications (25%) suggesting a reporting bias in the smaller series or perhaps regression to a truer mean in the larger studies [7,8].

This study was undertaken to review the complication rates and morbidity in a large series of consecutive patients as a means to determine the “in practice” success and complication rates as well as to assess the learning curve and patterns of morbidity in a large series.

**Methods**

We conducted a retrospective study of consecutive patients who underwent lotus petal flaps for vulvar reconstruction, between

September, 2008 when this surgery was adopted at our institution (the Canniesburn Plastic Surgery Unit of the Glasgow Royal Infirmary), and April, 2013. Patients were identified by departmental database as part of a quality assurance review. We included all patients who underwent extirpative surgery performed by members of the gynecology, gynecologic oncology, colorectal, or plastic surgery department at a single urban teaching hospital. All patients had documentation of a rotational flap described as lotus petal, gluteal fold, or horn flap in the operative report. Patients with advancement flaps, or in which the flap form could not be confirmed were excluded. All repairs were performed by a single consultant plastic surgeon (JRCT).

We reviewed the patients’ demographics, operative characteristics, as well as immediate and delayed post-operative complications. For the purpose of this study we used the following definitions: estimated blood-loss included loss from both the excisional and reconstructive portions of the case; any description of wound failure without necrosis, irrespective of whether there was displacement of the flap or requirement for closure was considered to be a superficial wound dehiscence; likewise, a diagnosis of cellulitis was ascribed to any patient for whom

**Table 1**  
Selected case series of lotus petal flaps in vulvar reconstruction.

Author (year)	Patients (N)	Flaps (N)	Co-morbid conditions	Flap loss – complete	Flap loss – partial	Wound separation	Reoperation	Medical complications
Yii and Niranjani (1996) [2]	8	13	NR					
Ragoowansi et al. (2004) [17]	40	56	NR	2 (4%)	6 (11%)	NR	2 (4%)	NR
Sawada et al. (2004) [6]	5	10	NR	0	1 (10%)	0	0	Cellulitis (2 patients)
Warrier et al. (2004) [18]	8	12	Dementia (13%) Renal transplant (13%)			0	0	Cellulitis (1 patient) Urinary incontinence (1 patient)
Salgarello et al. (2005) [19]	8	11	NR	0	3 (27%)	2 (18%)	4 (36%)	NR
Bodin et al. (2012) [5]	5	8	NR	0	0	2 (25%)	0	UTI (2 patients)
Buda et al. (2012) [20]	1	1	NR	0	0	0	0	
Current study	59	80	Tobacco abuse (37%) Diabetes (12%) Hypertension (25%) Hidradenitis (5%)	0	7 (12%)	12 (20%)	7 (12%)	Cellulitis (7 patients, 12%) DVT (1 patient, 2%)

NR, data not reported.  
UTI, urinary tract infection.  
DVT, deep venous thrombosis.

there was at least a documented clinical suspicion of cellulitis that resulted in treatment with antibiotics. It is acknowledged that these definitions would likely overestimate the true incidence of these complications. Defect size was calculated based on the measurements of the formalin-fixed pathology specimens using the formula for an ellipse ( $\pi \times r_1 \times r_2$ , where  $r_1$  and  $r_2$  are perpendicular radii). Previous work has demonstrated that post processing measurements likely underestimate the true excision size by approximately 30%, however no corrections for this were made [9].

Flaps were performed by the method described by Yii and Niranjani using either fascio-cutaneous or supra-fascial cutaneous flap as dictated by the depth of the defect (Fig. 1) [2]. Both tunneled and directly rotated flaps were included in the analysis.

Internal comparisons were made using chi-squared analysis for proportions and/or Student's t-test or Mann-Whitney U test for continuous variables as appropriate. A p-value of <.05 was considered statistically significant. Because this study was retrospective, sample size was dictated by inclusion of all available cases; therefore no power calculations were performed.

## Results

We identified 59 patients during the study period who underwent a total of 80 lotus petal flaps. The patient characteristics are listed in Table 2. In general, the patients' age distribution and medical comorbidities were similar to prospective Gynecologic Oncology Group studies suggesting that the population was not over-selected for favorable outcomes [10]. Patients with non-malignant conditions were significantly younger than patients with malignant conditions (mean age 50.1 years vs 64.9 years,  $p = 0.01$ ), and more apt to be current or former smokers (90% vs 35%,  $p = 0.003$ ). Concordant with their younger mean age, patients without malignancy had lower absolute prevalence of hypertension (22 vs 46%,  $p = 0.19$ ) and diabetes (11% vs 19%,  $p = 0.59$ ), though these differences were not statistically significant.

The average (range) surface area of the pathological specimens was 29 cm<sup>2</sup> [2] (5–99 cm<sup>2</sup> [2]). Twenty-two patients (37%) required bilateral flaps; unsurprisingly these patients had larger defects than patients with a single flap closure (37 cm<sup>2</sup> vs 24 cm<sup>2</sup> respectively,  $p = 0.046$ ) and higher estimated blood loss (325 cm<sup>3</sup> vs 148 cm<sup>3</sup>,  $p = 0.003$ ).

There were no intra-operative complications recorded. The median (range) of estimated blood loss was 200 cm<sup>3</sup> (50–600 cm<sup>3</sup>) for both the extirpative and reconstructive portions of the case.

Post-operative complications are listed in Table 3, but serious complications were rare. There was no donor site morbidity identified. There were no cases of complete flap loss and though partial flap loss

**Table 2**  
Patient characteristics.

Age (years)	59 (24–89)
Body Mass Index (kg/m <sup>2</sup> )	27 (19–34)
Indications	
Hidradenitis	3 (5.1%)
Vulvar dysplasia	12 (20.3%)
Vulvar cancer	39 (66.1%)
Colorectal disease	5 (8.5%)
Comorbidities	
Smoking	
Active	14 (23.7%)
Former	8 (13.6%)
Never	21 (35.6%)
Unknown	16 (27.1%)
Diabetes	
Yes	7 (11.9%)
No	40 (67.8%)
Unknown	12 (20.3%)
Hypertension	
Yes	15 (25.4%)
No	31 (52.5%)
Unknown	13 (22%)

**Table 3**

Complications from lotus-petal flaps: 80 flaps in 59 patients.

Complication	N (%) <sup>a</sup>
Cellulitis	7 (11.9%)
DVT (within 30 days)	1 (1.6%)
UTI	0
Hematoma	0
Superficial wound separation	12 (20.3%)
Partial flap loss	7 (11.9%)
Required reoperation	
Yes	3 (43%)
No	4 (57%)
Complete flap loss	0
Donor site complications	0
Delayed re-operation	4 (6.8%)

<sup>a</sup> Complications are reported as a percentage of patients (not flaps), without duplication.

was recorded for 7 of 80 flaps (8.8%) only three of these required operative revision prior to discharge and all were considered “minor losses.” One patient (1.3%) ultimately required a split thickness skin graft to achieve closure. Overall complication rates were not significantly higher among patients with 2 flaps (45% for patients with 2 flaps vs 30% for single flaps,  $p = 0.22$ ). Tunneling the flap under a skin bridge did not result in a significantly higher overall complication rate (43% vs 32% for those direct rotation,  $p = 0.50$ ). Complication rates were slightly higher in the second half of the study (43% vs 29%,  $p = 0.24$ ), but there was a trend towards larger defect size over the same periods (33 cm [2] vs 24 cm [2],  $p = 0.09$ ) suggesting that gains from the learning curve were offset by application in more difficult cases. Margin status among patients undergoing excision for malignancy, was positive in 3 of 19 (16%) in the first half of the study and 3 of 20 (15%,  $p = 0.95$ ) in the second half.

Four patients required a second surgery after hospital discharge. In two cases this was for the management of flap loss not responding to conservative measures (typically release of the suture line with wet to dry dressing changes), and in two cases this was for management of symptoms caused by healed flaps (one case each of stenosis of the introitus and lateral stricture).

## Discussion

Our results indicate that the lotus petal flap is a viable and versatile option for closure of intermediate to large defects of the vulva, vagina and perineum. Donor site morbidity is low and significant flap loss is uncommon but can occur. Most cases of partial flap loss could be managed conservatively with wound care only or skin grafting, and long term outcome complications were rare. Medical morbidity was more common than in previous reports, but easily managed in most cases, and likely reflects a reporting bias.

The lotus-petal fascio-cutaneous flap, irrespective of the specific design, is supplied primarily not only by perforating branches of the internal pudendal artery, but also through non-perforating branches of the inferior gluteal artery, and perforators originating from the inferior gluteal artery and running through the gluteus maximus muscle which allows the surgeon significant “latitude” in optimizing reconstructive surgery at both the donor and defect sites [11]. Further, in the absence of a need for bulk, the fascio-cutaneous flaps provide a more anatomically appropriate thickness for coverage of the vulvar and perineum than myocutaneous flaps. Though multiple advancement flaps are suitable for vulvo-perineal reconstruction, including the gluteus flap [12], the V to Y advancement [13], and the pudendal thigh flap [14], the gluteal fold version of the lotus petal flap best respects a natural anatomic fold at the donor site leading to the most cosmetic donor site closure (Fig. 1D). Additionally, the lotus petal flap can be based some distance from even a wide radical excision, allowing use when more proximal flap bases have been excised [15].

The reliability of this flap allows for both a tunneled and directly rotated flap design. Though we did not observe significant differences in outcomes or morbidity between the different flap designs, we favor the tunneled approach in patients with relatively poorer pre-operative nutritional status as wound failure in a direct rotational flap leaves a larger iatrogenic defect. While the tunneled design may leave a small tissue bulge under the bridge, this is usually symptomatic only temporarily and rarely requires secondary “debulking” revision as evidenced by the low number of secondary surgeries seen in this study.

The strengths of this study include the large sample size, selection of consecutive cases over multiple years, and consistency of the surgical team. Most reports to date include less than 10 patients, with inclusion criteria reported variably. While these reports certainly establish feasibility, it is difficult to assess the risks and morbidity that might be expected when applying this flap broadly. Our inclusion of sequential patients prevents a selection/reporting bias that cannot be excluded in smaller series without reported inclusion criteria. While previous reports have typically reported more favorable complication rates, the possibility of selection bias cannot be excluded in such small samples, and in fact is suggested by a reported complication rate for this islanded flap, that is similar to that reported in other large series for transposition flaps of similar size [16]. The duration of case collection and consistency of the surgeon performing closure also allows us to assess the surgical “learning curve.” Our data demonstrates that while the complication rates did not change significantly the mean defect size was notably larger in the second half of the study, suggesting that a broadening of the clinical application of the lotus petal flap was occurring without a formal analysis of upper limits of feasibility. It might also be inferred that the successful application of the flap in the first half of the study resulted in increasing confidence in the resecting surgeons obtaining wider margins, though the rate of positive margins was low both early and late in the study.

The weaknesses of this study are those inherent to all retrospective reviews. Reporting of clinical parameters such as wound defect size was inconsistent and the methods of determining these assessments were not reported in most cases. We attempted to limit the data collected to objective measure insofar as possible and where possible estimated conservatively; for example in choosing the pathologic specimen size over the defect size estimated in surgery we have likely underestimated the actual flap sizes as a result of processing. Likewise, though all observed complications are reported, follow-up was not standardized leading to a possible underestimation of delayed complications. Lastly, in the absence of prospectively collected quality of life data, we were unable to accurately assess the patients' satisfaction with their outcome or the short and long term impact on quality of life.

## Conclusion

This large series demonstrates that the lotus petal version of the lotus petal fascio-cutaneous flap is an excellent option for closure of medium to large sized vulvo-vaginal defects. Complete flap loss was not encountered, and partial flap loss was uncommon. Post-operative morbidity, though higher than in previous reports, was objectively low and in most cases easily managed. We suspect that the current

report more accurately reflects the “true” incidence of complications and should be used to guide patient discussion regarding the risks and benefits of this surgery. Though this report confirms the viability of this technique, additional research on functionality and patient satisfaction is needed.

## Conflict of interest statement

None of the authors declare any conflicts relevant to design or results of this study.

## References

- [1] Lin JY, DuBeshter B, Angel C, Dvoretzky PM. Morbidity and recurrence with modifications of radical vulvectomy and groin dissection. *Gynecol Oncol* 1992;47(1):80–6.
- [2] Yii NW, Niranjan NS. Lotus petal flaps in vulvo-vaginal reconstruction. *Br J Plast Surg* 1996;49(8):547–54.
- [3] Nakamura Y, Ishitsuka Y, Nakamura Y, Xu X, Hori-Yamada E, Ito M, et al. Modified gluteal-fold flap for the reconstruction of vulvovaginal defects. *Int J Dermatol* 2010;49(10):1182–7.
- [4] Ninomiya R, Kishi K, Imanishi N, Nakajima H, Nakajima T. Reconstruction of vulva using pudendal thigh gluteal fold bilobed flap. *J Plast Reconstr Aesthet Surg* 2010;63(2):e130–2.
- [5] Bodin F, Weitbruch D, Seigle-Murandi F, Volkmar P, Bruant-Rodier C, Rodier JF. Vulvar reconstruction by a “supra-fascial” lotus petal flap after surgery for malignancies. *Gynecol Oncol* 2012;125(3):610–3.
- [6] Sawada M, Kimata Y, Kasamatsu T, Yasumura T, Onda T, Yamada T, et al. Versatile lotus petal flap for vulvoperineal reconstruction after gynecological ablative surgery. *Gynecol Oncol* 2004;95(2):330–5.
- [7] Franchelli S, Leone MS, Bruzzone M, Muggianu M, Puppo A, Gustavino C, et al. The gluteal fold fascio-cutaneous flap for reconstruction after radical excision of primary vulvar cancers. *Gynecol Oncol* 2009;113(2):245–8.
- [8] Windhofer C, Papp C, Staudach A, Michlits W. Local fasciocutaneous infragluteal (FCI) flap for vulvar and vaginal reconstruction: a new technique in cancer surgery. *Int J Gynecol Cancer* 2012;22(1):132–8.
- [9] Dauendorffer JN, Bastuji-Garin S, Guero S, Brousse N, Fraitag S. Shrinkage of skin excision specimens: formalin fixation is not the culprit. *Br J Dermatol* 2009;160(4):810–4.
- [10] Levenback CF, Ali S, Coleman RL, Gold MA, Fowler JM, Judson PL, et al. Lymphatic mapping and sentinel lymph node biopsy in women with squamous cell carcinoma of the vulva: a gynecologic oncology group study. *J Clin Oncol* 2012;30(31):3786–91.
- [11] Hashimoto I, Murakami G, Nakanishi H, Sakata-Haga H, Seike T, Sato TJ, et al. First cutaneous branch of the internal pudendal artery: an anatomic basis for the so called gluteal fold flap. *Okajimas Folia Anat Jpn* 2001;78:23–30.
- [12] Ogino M, Sakamoto T, Inoue J, Dobashi K, Okinaga S, Arai K. Reconstruction of surgical defects using the gluteus maximus myocutaneous flap following radical vulvectomy. *Asia Oceania J Obstet Gynaecol* 1992;18:23–9.
- [13] Lee JH, Shin JW, Kim SW, Oh DY, Park JS, Hur SY, Rhie JW, Ahn ST. Modified gluteal fold V-Y advancement flap for vulvovaginal reconstruction. *Ann Plast Surg* 2012 [Sep 28, Epub ahead of print].
- [14] Gleeson NC, Baile W, Roberts WS, Hoffman MS, Fiorica JV, Finan MA, et al. Pudendal thigh fascio-cutaneous flaps for vaginal reconstruction in gynecologic oncology. *Gynecol Oncol* 1994;54:269–74.
- [15] Wee JT, Joseph VT. A new technique of vaginal reconstruction using neurovascular pudendal-thigh flaps: a preliminary report. *Plast Reconstr Surg* 1989;83:701–9.
- [16] Burke TW, Morris M, Levenback C, Gershenson DM, Wharton JT. Closure of complex vulvar defects using local rhomboid flaps. *Obstet Gynecol* 1994;84:1043–7.
- [17] Ragoowansi R, Yii N, Niranjan N. Immediate vulvar and vaginal reconstruction using gluteal fold flap: long-term results. *Br J Plast Surg* 2004;5:406–10.
- [18] Warrior SK, Kimble FW, Blomfield P. Refinements in the lotus petal flap repair of the vulvo-perineum. *ANZ J Surg* 2004;74:684–8.
- [19] Salgarello M, Farallo E, Barone-Adesi L, Cervelli D, Scambia G, Salerno G, Margariti PA. Flap algorithm in vulvar reconstruction after radical, extensive vulvectomy. *Ann Plast Surg* 2005;54(2):184–90 [Feb].
- [20] Buda A, Confalonieri PL, Rovati LC, Signorelli M, DelBene M. Tunneled modified lotus petal flap for surgical reconstruction of severe introital stenosis after radical vulvectomy. *Int J Surg Case Rep* 2012;3:299–301.